

## Research Article

# Signs and Symptoms of Genital Lichen Sclerosus in Women Seeking Autologous Adipose-Derived Stem Cell Treatment

Nathan Newman\*, Nualla N Dolphin and Gabriella R Newman

Private Practice, USA

## \*Corresponding authors

Nathan Newman, 9301 Wilshire Blvd Ste 303, Beverly Hills, CA 90210, Tel: 310-273-3344; Fax: 310-273-765; Email: doctor@nathannewmanmd.com

Submitted: 13 May 2015

Accepted: 17 August 2015

Published: 19 August 2015

ISSN: 2333-6439

## Copyright

© 2015 Newman et al.

## OPEN ACCESS

## Keywords

- Lichen sclerosus
- Genital lichen sclerosus
- Stem cell
- Autoimmune

## Abstract

Lichen Sclerosus is a debilitating disease that causes chronic inflammation of the anogenital region. Many patients with Lichen Sclerosus of the anogenital area report unsuccessful results with standard treatments including steroids, calcineurin inhibitors, and/or hormone therapy. These patients presented to our clinic seeking autologous adipose-derived stem cell treatment (AASCT).

**Materials and Methods:** 90 women, aged 20-76, who presented to our clinic from 2011 to 2014 with Lichen Sclerosus were given questionnaires developed by our clinic. 86 of these patients completed the questionnaire about their disease symptoms and quality of life indicators in relation to their symptoms.

**Results:** The most common signs and symptoms reported by the patients presenting to our clinic with Lichen Sclerosus of the genitalia were: pruritus (97%), discomfort (95%), pigment changes (93%), pain (93%), and burning (93%). Other common symptoms included altered sensation (86%), sclerosis (84%), changes in anatomy (81%), tearing (80%), fusing (76%), fissures (71%), ulcerations (60%), and blistering (45%).

The most common activities of daily living that patients reported difficulty with were: intercourse (94%), wearing pants or underwear (79%), exercising (67%), bowel movements (61%), and voiding (60%).

**Conclusion:** Patients who presented to our clinic seeking AASCT reported inadequate relief for their symptoms from standard available therapies. Patients reported a substantial decrease in quality of life from the disease, which prevented sexual relations, exercise, and daily activities. Having felt despair, anxiety, and even depression in their failure to respond to standard available treatments, these patients sought alternative therapies, including AASCT at our clinic.

## ABBREVIATIONS

AASCT: Autologous Adipose-derived Stem Cell Treatment;  
SCC: Squamous Cell Carcinoma

## INTRODUCTION

Lichen Sclerosus is a debilitating disease that can result in significant psychosocial distress and anxiety affecting quality of life [1,2]. Regrettably, Lichen Sclerosus is commonly undiagnosed, misdiagnosed, and untreated; resulting in considerable physical, emotional, and sexual difficulties, including irreversible destruction of the genitalia [3-8].

The true incidence rate for Lichen Sclerosus is unknown, as

this disease often goes undiagnosed [9]. However, rates between 1 in 30 and 1 in 1,000 have been reported [3,10,11]. Lichen Sclerosus can affect men and women at any age. Hormonal changes may exacerbate the disease and therefore the onset of symptoms is noted more frequently at menarche or in post-menopausal woman [12-14]. Women are 6-10 times more frequently affected by Lichen Sclerosus than men [14-16].

The disease has varying degrees of presentation; some patients present with intolerable itching and burning, others with erosions, blisters, and/or severe fusing. As the symptoms may overlap with other more-common diseases, Lichen Sclerosus is commonly misdiagnosed [17]. Patients report that the onset of symptoms is usually associated with a period of physical,

emotional, or hormonal stress. The cosmetic appearance, lack of intimacy, embarrassment, and stress of the condition has a profound effect on mental health [18].

A diagnosis of Lichen Sclerosus can be achieved by a detailed history and clinical examination. If needed, a biopsy may be taken to confirm the diagnosis. There may be an increased risk for squamous cell carcinoma (SCC) of the genitalia in Lichen Sclerosus patients from their chronic inflammation; studies have shown that 5% of patients with untreated Lichen Sclerosus may develop squamous cell carcinoma [19]. If SCC is suspected then a biopsy should be taken to rule out neoplasia.

Currently, the first line of treatment for Lichen Sclerosus is the ultra-potent corticosteroid Clobetasol propionate 0.05% [20]. Patients are often instructed to apply the ointment twice a day for 3 months [14,21] or until symptoms resolve. The steroid ointment can be very effective for some patients, giving symptomatic relief and in some cases temporarily putting the disease into remission [9]. Long-term, chronic use of this steroid can cause erythema, thinned skin, irritation, and atrophy [22]. Another potential hazard of Clobetasol propionate 0.05% is the risk of steroid dependence, potentially causing rebound "flares" upon discontinuation or result in steroid induced atrophy of the tissues [23].

Second-line treatment options for patients that do not experience relief with topical potent steroids are topical calcineurin inhibitors such as tacrolimus, either alone or in addition to the topical steroid [24]. Additional treatment options include topical and/or oral hormone replacement therapy. Second line treatments have not shown to be as effective as Clobetasol propionate 0.05% [25]. In advanced cases of sclerotic disease, surgical intervention has been tried, however, many studies advise against this and only recommend when malignancy is noted or sclerotic changes interfere with daily activities [4, 26-30].

In a PubMed search for vulvar Lichen Sclerosus from 2010-2015 only 182 published articles were available, The published data regarding the symptoms of Lichen Sclerosus and the response rate to available treatment options is limited. It is unknown whether specific symptoms have a better response rate to particular treatments.

## MATERIALS AND METHODS

90 women, aged 20-76, who presented on their first visit to our clinic from 2011 to 2014 with Lichen Sclerosus were asked to complete a questionnaire. The questionnaire was developed by our clinic to evaluate their disease symptoms and quality of life indicators as well as current and past treatment regimens in relation to their symptoms. A retrospective chart review was carried out on the 86 women who completed the questionnaire. In our clinic, patients presented with a broad spectrum of signs and symptoms. At one end of the spectrum, patients presented with very severe and advanced clinical signs of Lichen Sclerosus with severe sclerosis and obliteration of the vaginal anatomy but were asymptomatic. At the other end of the spectrum, patients reported severe symptoms of itching, burning or discomfort, yet on physical examination showed mild signs of Lichen Sclerosus.

Patients were asked to rank their symptoms on a scale of 0-5 (0 being no symptom, 5 being most severe symptom) on a daily basis and during a flare. Patients were also asked to rank specific activities of daily living on a scale of 0-5 (0 being no difficulty with that activity, 5 being unable to perform that activity). In addition, we asked our patients to rank the severity of discomfort that coincided with each activity (0 was no impediment carrying out that activity, 5 was unable to perform that activity). The data was reviewed and calculated for the most common and severe signs and symptoms of Lichen Sclerosus, as well as for difficulty in carrying out activities of daily living. The percentage of patients with the specified symptom was based on a non-zero survey score given for the symptom by the patient. If the survey response was a zero score (0 being no symptom) on a daily basis and also during a flare, then the patient was considered to not have that symptom.

## RESULTS AND DISCUSSION

In the 86 patients that completed the questionnaire in our clinic from 2011-2014 the average age was 48.7 years, with a range from 20 to 76 years old. The mean time between onset of symptoms and diagnosis was 5.42 years, with a range of 0 to 43 years, and a median of 2 years. A biopsy was carried out in 60% of our patient population.

All patients that presented to our clinic from 2011-2014 who completed the questionnaire had used Clobetasol propionate 0.05% and/or other steroids with minimal or no relief. Some patients report burning and irritation upon application which could be due to an allergy/sensitivity to the base of the ointment [20] or, although rare, the steroid itself. Failure to respond may be due to inadequate education regarding medication use and/or duration of treatment. Some patients tried second line treatments and alternative medicine treatments which also failed to alleviate their symptoms.

The most common symptoms experienced by patients suffering from Lichen Sclerosus of the genitalia at our clinic, despite trying conventional treatments, were as follows (figure 1): pruritus (97%), discomfort (95%), pigment changes (93%), pain (93%), and burning (93%). Other common symptoms included altered sensation (86%), sclerosis (84%), changes in anatomy (81%), tearing (80%), fusing (76%), fissures (71%), ulcerations (60%), and blistering (45%). Most patients report had fluctuations in the severity of their symptoms, yet others had chronic and consistent symptoms of burning and/or itching. Exacerbation of symptoms, which patients commonly refer to as a "flare", usually occur around their menses and/or during times of physical or emotional stress. Patients reported that Lichen Sclerosus symptoms during a flare were significantly more severe than on a daily basis.

Severity of difficulty with the most common signs and symptoms was most noted with: pruritus (daily 2.7, flare 3.9), discomfort (daily 3.4, flare 4.3), pigment changes (daily 3.3, flare 3.8), pain (daily 3.0, flare 4.1), burning (daily 2.9, flare 4.0), altered sensation (daily 3.1, flare 3.5), sclerosis (daily 2.6, flare 3.2), changes in anatomy (daily 3.2, flare 3.5), tearing (daily 2.6, flare 3.4), fusing (daily 2.6, flare 2.9), fissures (daily 1.9, flare 2.7), ulcerations (daily 1.5, flare 2.3), and blistering (daily 1.1, flare 1.4).

Physical changes from Lichen Sclerosus were defined as below. Changes in anatomy were defined as what the patient perceived as anatomical changes including atrophy, fusing, and/or sclerosis. Sclerosis, or as patients referred to as scarring, was defined as visible sclerotic changes of the tissues, with or without contractures causing narrowing of the vaginal opening, burying of the clitoris, and/or changes in urinary stream due to thickening of the tissue. Fusing was defined as effacement and disappearance of the labia minora and/or prepuce. Tearing was defined as small, superficial cuts that healed within 2-3 weeks and were commonly found along the prepuce, labia minora, fourchette, peri-anal, and gluteal fold. Fissures, which were found to commonly occur along the perineum and anal verge, were defined as deep, non healing, linear cuts that did not go beyond the dermal layer. Altered sensation referred to either hypersensitivity or hyposensitivity of the tissues, most commonly affecting the clitoral area. Pigmentary changes referred to hyperpigmentation, hypopigmentation, and/or leukokraurosis.

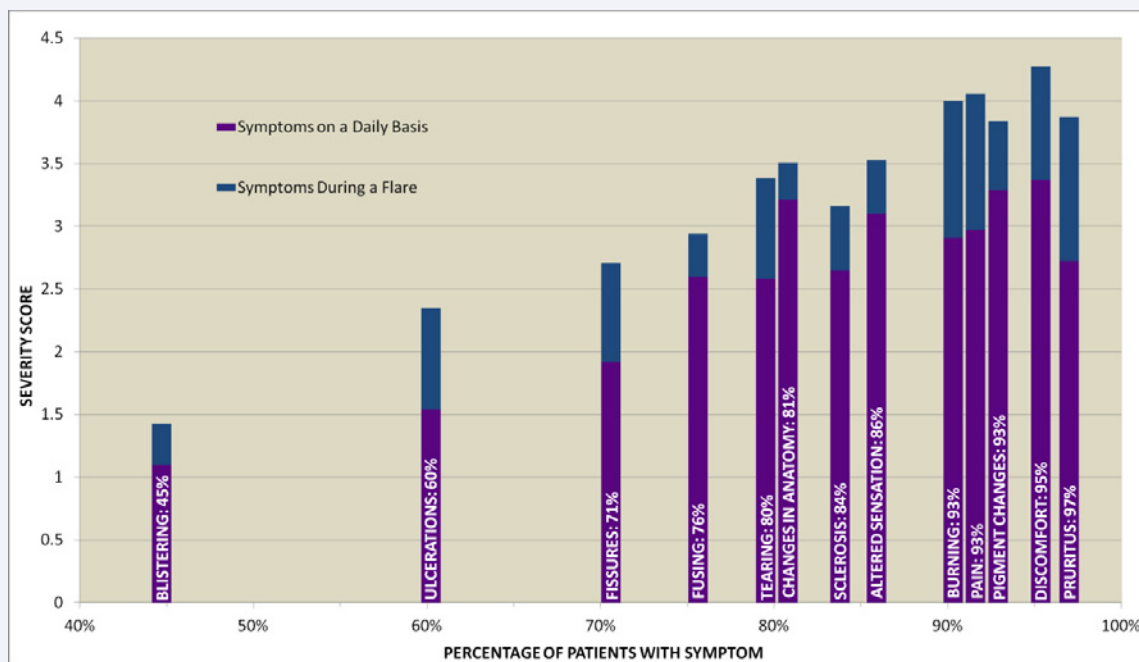
Difficulty and/or inability to carry out specific activities of daily living were most commonly associated with (figure 2): intercourse (94%), wearing pants, jeans, or underwear (79%), exercising (67%), bowel movements (61%), and voiding (60%). Severity of difficulty with daily activities was most noted with: intercourse (3.9), wearing pants/underwear (2.6), exercising (2.2), bowel movements (1.7) and voiding (1.7). Difficulty with intercourse was most often due to pain, tearing, and/or fear of discomfort. Wearing pants/underwear and exercise was often an issue with patients as the friction caused irritation, pain, and often triggered a flare. Bowel movements were associated with discomfort, tearing, and bleeding. Urination often caused severe burning upon contact with sensitive and inflamed tissues.

## CONCLUSION

To date, this is the first study evaluating the signs and symptoms, the course of disease, the treatments used, and the time to diagnosis for patients with Lichen Sclerosus seeking autologous adipose-derived stem cell treatment (AASCT). As confirmed in other published reports, failure of clinicians to recognize the disease, despite long standing signs and symptoms was a significant problem in our patient population [31]. Many patients felt that even when diagnosed, their physician had little knowledge about the disease or how to treat it.

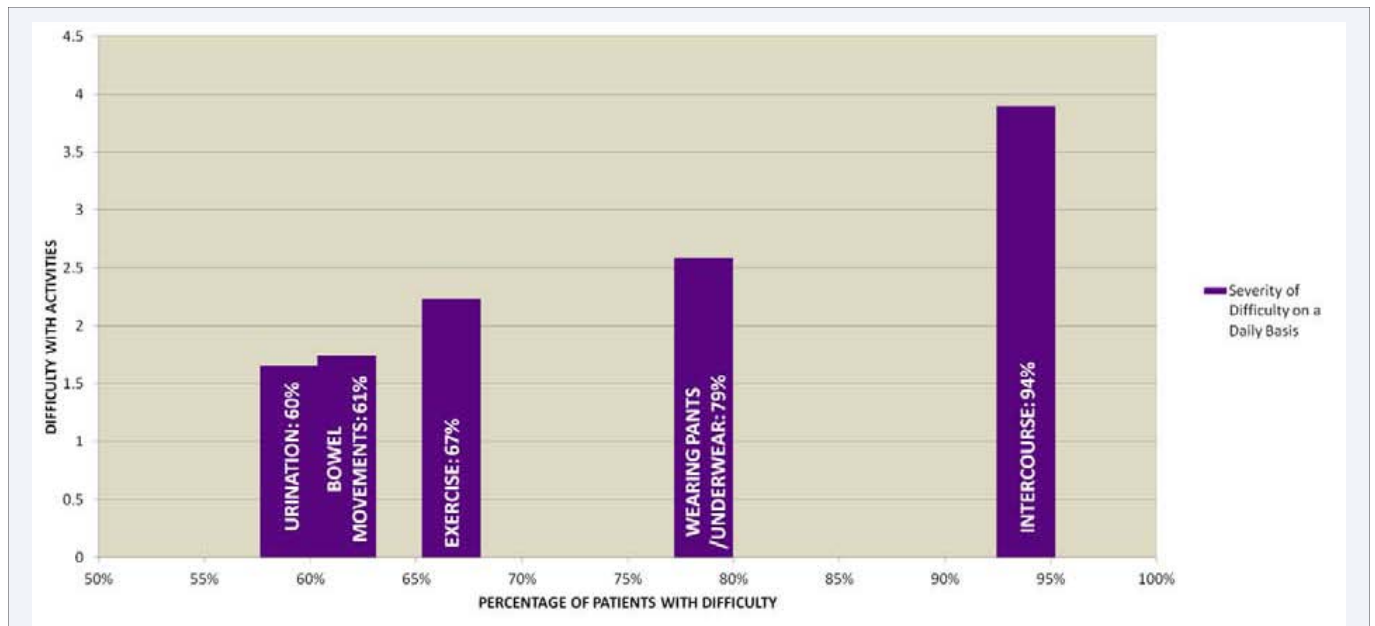
A patient should be diagnosed clinically with a thorough history and physical. If necessary the diagnosis may be confirmed with a biopsy. It is important to recognize that a nonspecific biopsy does not rule out Lichen Sclerosus, but a positive biopsy result may be used to confirm the diagnosis [32,33].

Our data revealed that the most common signs and symptoms often correlated to the most severe symptoms. Most of our patient population reported a significant decrease in quality of life as they are unable to have intercourse, wear pants, underwear, or exercise due to the severe pruritus, discomfort, pain, and burning. In our review of the literature we found no published data to conclude that specific symptoms respond better to one specific treatment regimen over another. It is unknown if there is a correlation between particular symptoms and their response to treatments, and we cannot definitively say why some patients respond to traditional treatments and others do not. Our population of patients showed no obvious link to any specific symptoms; there was a large variation in age, length of disease, disease progression, signs, and symptoms.



**Figure 1** Women with Genital Lichen Sclerosus: Commonality and Severity of Signs and Symptoms.

Symptoms with the same percentage (e.g. 93%) are spread horizontally on the chart to make the chart more readable. Otherwise, the bars in the chart around 93% would be overlapping and difficult to read.



**Figure 2** Women with Genital Lichen Sclerosis: Commonality and Severity of Difficulty with Daily Activities.

Patients reported seeking multiple treatments and physicians in their search to alleviate their symptoms. Often patients reported initial symptoms involving itching, burning, and discomfort in the anogenital region, years before menopause. Many patients reported being diagnosed with a presumed yeast infection and prescribed a course of antifungals such as fluconazole. As patients were not responsive to such treatments, the disease progressed, causing atrophy and dryness that were often attributed to normal post-menopausal changes. These patients were then prescribed hormone replacement therapy. Many patients have been misdiagnosed with urinary tract infections, fungal infections, sexually transmitted diseases (commonly Herpes Simplex Virus), and/or psychiatric problems. This delay in diagnosis can be detrimental to a patient's wellbeing as they are suffering from this debilitating disease with no answers or relief from their physicians. In our patient population, a mean time of 5.42 years was noted between onset of symptoms and a diagnosis. This not only led to decreased quality of life, but Lichen Sclerosis left untreated can cause irreversible damage to the skin. Clinicians should be aware of the signs and symptoms of Lichen Sclerosis to ensure it is included in the differential diagnosis, especially those patients that are not responsive to the more common presumed diagnoses for vulvar discomfort, itching, and/or burning.

As these patients did not experience adequate symptomatic relief with standard treatment options (such as topical steroid or hormone creams/ointments), many patients turned to the internet for possible alternative therapies. The sharing of information via various internet websites and/or blogs has brought many patients to seek Autologous Adipose-derived Stem Cell Treatment (AASCT) in the hope of improving their condition. The concept of using autologous stem cell therapy in the treatment of autoimmune skin diseases such as Lichen Sclerosis is based on the reported effectiveness in treating other autoimmune conditions such as graft versus host [34] and sick

cell disease [35].

Lichen Sclerosis patients wishing to undergo AASCT treatment seem to have many common reasons for pursuing this alternative treatment modality. First and foremost, they did not experience adequate relief from traditional treatment options. Secondly, many patients report losing faith in healthcare providers because they experienced a significant delay in diagnosing Lichen Sclerosis. Third, all patients report significant decreased quality of life, despite using traditional treatment options, and therefore looked for an alternative treatment. Fourth, patients seek a long term solution for their condition. Lastly, patients desired early intervention with AASCT in hopes of preventing disease progression.

The most common signs and symptoms of Lichen Sclerosis are often overlooked and presumed to be commonly a yeast infection. To minimize delay in diagnosing Lichen Sclerosis, it is vital to educate physicians about the disease so that it is part of the differential diagnosis. Even after being diagnosed, the patients in our clinic report inadequate relief with the standard treatment protocols as prescribed by their physician and wish to pursue AASCT as an alternative to help alleviate their symptoms.

## ACKNOWLEDGEMENTS

We would like to thank Mr. Jeff Grey for helping us with the data analysis.

## REFERENCES

1. Kunstfeld R, Kirnbauer R, Stingl G, Karhofer FM. Successful treatment of vulvar lichen sclerosis with topical tacrolimus. *Arch Dermatol.* 2003; 139: 850-852.
2. Dalziel KL. Effect of lichen sclerosis on sexual function and parturition. *J Reprod Med.* 1995; 40: 351-354.
3. Chi CC, Kirtschig G, Baldo M, Lewis F, Wang SH, Wojnarowska F. Systematic review and meta-analysis of randomized controlled



- trials on topical interventions for genital lichen sclerosis. *J Am Acad Dermatol.* 2012; 67: 305-312.
4. Wedel N, Johnson L. Vulvar Lichen Sclerosus: Diagnosis and Management. *Journal for Nurse Practitioners.* 2014; 10: 42-48.
  5. Gurumurthy M, Morah N, Gioffre G, Cruickshank ME. The surgical management of complications of vulval lichen sclerosis. *Eur J Obstet Gynecol Reprod Biol.* 2012; 162: 79-82.
  6. Thorstensen KA, Birenbaum DL. Recognition and management of vulvar dermatologic conditions: lichen sclerosis, lichen planus, and lichen simplex chronicus. *J Midwifery Womens Health.* 2012; 57: 260-275.
  7. Vulvar lichen sclerosis may be treated effectively with topical corticosteroids, but long-term surveillance is required. *Drugs Ther Perspect.* 2010; 26: 16-19.
  8. Chi CC, Kirtschig G, Baldo M, Brackenbury F, Lewis F, Wojnarowska F. Topical interventions for genital lichen sclerosis. *Cochrane Database Syst Rev.* 2011; 12.
  9. Renaud-Vilmer C, Cavelier-Balloy B, Porcher R, Dubertret L. Vulvar lichen sclerosis: effect of long-term topical application of a potent steroid on the course of the disease. *Arch Dermatol.* 2004; 140: 709-712.
  10. Leibovitz A, Kaplun V V, Saposhnicov N, Habet B. Vulvovaginal examinations in elderly nursing home women residents. *Arch Gerontol Geriatr.* 2000; 31: 1-4.
  11. Tasker GL, Wojnarowska F. Lichen sclerosis. *Clin Exp Dermatol.* 2003; 28: 128-133.
  12. Pugliese JM, Morey AF, Peterson AC. Lichen sclerosis: review of the literature and current recommendations for management. *J Urol.* 2007; 178: 2268-2276.
  13. Meyrick Thomas RH, Ridley CM, McGibbon DH, Black MM. Lichen sclerosis et atrophicus and autoimmunity--a study of 350 women. *Br J Dermatol.* 1988; 118: 41-46.
  14. Cooper SM, Gao XH, Powell JJ, Wojnarowska F. Does treatment of vulvar lichen sclerosis influence its prognosis? *Arch Dermatol.* 2004; 140: 702-706.
  15. Canady J, Karrer S, Fleck M, Bosserhoff AK. Fibrosing connective tissue disorders of the skin: molecular similarities and distinctions. *J Dermatol Sci.* 2013; 70: 151-158.
  16. Powell JJ, Wojnarowska F. Lichen sclerosis. *Lancet.* 1999; 353: 1777-1783.
  17. Günthert AR, Duclos K, Jahns BG, Krause E, Amann E, Limacher A, Mueller MD. Clinical scoring system for vulvar lichen sclerosis. *J Sex Med.* 2012; 9: 2342-2350.
  18. Shasi PB, Chapman HT, Evans DT, Jaleel H. Psychological and psychiatric morbidity in lichen sclerosis in a cohort recruited from a genitourinary medicine clinic. *Int J STD AIDS.* 2010; 21: 17-18.
  19. Danby CS, Margesson LJ. Approach to the diagnosis and treatment of vulvar pain. *Dermatol Ther.* 2010; 23: 485-504.
  20. Smith YR, Haefner HK. Vulvar lichen sclerosis : pathophysiology and treatment. *Am J Clin Dermatol.* 2004; 5: 105-125.
  21. McPherson T, Cooper S. Vulval lichen sclerosis and lichen planus. *Dermatol Ther.* 2010; 23: 523-532.
  22. Lowell A Goldsmith, Stephen I Katz, Barbara A Gilchrist, Amy S Paller, David J Leffell, Klaus Wolff. *Fitzpatrick's Dermatology in General Medicine Fifth Edition, Volume II, 1999: 2713-2717.*
  23. Gorgievska Sukarowska B, LipozenciĀ J. Topical management of psoriasis - corticosteroids and sparing corticosteroid therapy. *Acta Dermatovenerol Croat.* 2006; 14: 188-196.
  24. Wehbe-Alamah H, Kornblau BL, Haderer J, Erickson J. Silent no more! The lived experiences of women with lichen sclerosis. *J Am Acad Nurse Pract.* 2012; 24: 499-505.
  25. Patsatsi A, Kyriakou A, Vavilis D, Mantas A, Patsialas C, Sotiriadis D. A therapeutic approach for female, relapsing genital lichen sclerosis: a single-center study. *J Dermatolog Treat.* 2013; 24: 336-339.
  26. Freedberg I, Eisen A, Wolff K. *Fitzpatrick's Dermatology In General Medicine Fifth Edition, Volume I, 1999: 1382-1386.*
  27. August PJ, Milward TM. Cryosurgery in the treatment of lichen sclerosis et atrophicus of the vulva. *Br J Dermatol.* 1980; 103: 667-670.
  28. Sommer J, Renziehausen K, Neuhauser H, Neuhauser M, Hecker J. [Cryotherapy of vulvar precancerous conditions--results of 12 years' treatment]. *Arch Geschwulstforsch.* 1985; 55: 341-349.
  29. Kartamaa M, Reitamo S. Treatment of lichen sclerosis with carbon dioxide laser vaporization. *Br J Dermatol.* 1997; 136: 356-359.
  30. Abramov Y, Elchalal U, Abramov D, Goldfarb A, Schenker JG. Surgical treatment of vulvar lichen sclerosis: a review. *Obstet Gynecol Surv.* 1996; 51: 193-199.
  31. Virgili A, Borghi A, Toni G, Minghetti S, Corazza M. Prospective clinical and epidemiologic study of vulvar lichen sclerosis: analysis of prevalence and severity of clinical features, together with historical and demographic associations. *Dermatology.* 2014; 228: 145-151.
  32. Fistarol SK, Itin PH. Diagnosis and treatment of lichen sclerosis: an update. *Am J Clin Dermatol.* 2013; 14: 27-47.
  33. Murphy R. Lichen sclerosis. *Dermatol Clin.* 2010; 28: 707-715.
  34. Ringdén O, Uzunel M, Rasmusson I, Remberger M, Sundberg B, Lönnies H, Marschall HU. Mesenchymal stem cells for treatment of therapy-resistant graft-versus-host disease. *Transplantation.* 2006; 81: 1390-1397.
  35. Hsieh MM, Kang EM, Fitzhugh CD, Link MB, Bolan CD, Kurlander R, Childs RW. Allogeneic hematopoietic stem-cell transplantation for sickle cell disease. *N Engl J Med.* 2009; 361: 2309-2317.

#### Cite this article

Newman N, Dolphin NN, Newman GR (2015) Signs and Symptoms of Genital Lichen Sclerosus in Women Seeking Autologous Adipose-Derived Stem Cell Treatment. *Med J Obstet Gynecol* 3(4): 1067.